

# A Step-by-Step Description of the DK Crush Technique

An overview of the materials required and how to perform the technique, with technical tips.

BY JUN-JIE ZHANG, MD, AND SHAO-LIANG CHEN, MD

Percutaneous coronary intervention (PCI) with drug-eluting stent (DES) implantation for coronary bifurcation lesions is associated with less favorable clinical outcomes compared with PCI of nonbifurcation lesions.<sup>1</sup> Provisional stenting (PS) is considered the preferable approach for most simple coronary bifurcation lesions.<sup>2</sup> However, a systematic two-stent approach is frequently required for bifurcation lesions with a side branch (SB) > 2.75 mm in diameter, SB lesion length ≥ 5 mm, or inaccessible SB after main vessel (MV) stenting.<sup>3</sup> The recently published DEFINITION II study showed that a two-stent approach is superior to PS in reducing target lesion failure (TLF) in patients with complex bifurcation lesions based on DEFINITION criteria (double kissing [DK] crush, 77.8%).<sup>4</sup> Furthermore, the superiority of DK crush to culotte stenting has been demonstrated in several randomized controlled trials.<sup>5-8</sup> The findings of the ULTIMATE study suggest that the clinical results of DK crush could be enhanced if the procedure is guided by intravascular ultrasound (IVUS).<sup>9</sup> To this end, the DKCRUSH VIII study (NCT03770650) was designed to evaluate the differences in efficacy and safety between IVUS- and angiography-guided DK crush stenting in patients with complex true bifurcation lesions. Generally, the DK crush technique consists of twice crushing, twice rewiring, and twice kissing balloon inflation (KBI). This article provides a step-by-step description of the DK crush stenting approach guided by IVUS in complex bifurcation lesions.

## DEFINITION OF COMPLEX CORONARY BIFURCATION LESION

Medina classification, the most commonly used classification in clinical practice,<sup>10</sup> does not take into account specific lesion characteristics (including

calcification, bifurcation angle, lesion length, etc), which can guide stent selection and clinical outcome. Chen et al reported the DEFINITION criteria, which consist of major and minor angiographic criteria. For distal left main (LM) bifurcations, major criteria are SB lesion length ≥ 10 mm and SB diameter stenosis ≥ 70%; for non-LM bifurcation lesions, major criteria are SB lesion length ≥ 10 mm and SB diameter stenosis ≥ 90%.<sup>11</sup> Additionally, there are six minor criteria: moderate to severe calcification, multiple lesions, bifurcation angle < 45° or > 70°, MV reference vessel diameter (RVD) < 2.5 mm, thrombus-containing lesions, and MV lesion length ≥ 25 mm. A complex bifurcation lesion is defined by the presence of one major criterion plus any two minor criteria. Figure 1 angiographically demonstrates a complex distal LM bifurcation, as reflected by left circumflex (LCX) lesion length ≥ 10 mm and LCX diameter stenosis ≥ 70%, coupled with severe calcification and multiple lesions.

## DK CRUSH MATERIALS

For most bifurcation lesions, the DK crush technique can be performed using a 6-F guide catheter via radial access. A 7-F guide catheter via radial/femoral access is mainly used if both daughter vessels have a diameter > 3.5 mm. The materials used are as follows: two workhorse wires, a 2.5- X 15-mm semicompliant balloon; 3- X 12-mm, 3.5- X 12-mm, and 4.5- X 8-mm noncompliant balloons; and 3- X 29-mm and 3.5- X 33-mm DESs. We use a commercially available IVUS imaging system with a 40-MHz mechanical transducer (Boston Scientific Corporation).

## HOW I DO IT

To begin, advance two workhorse wires into the distal left anterior descending artery (LAD) and LCX after a

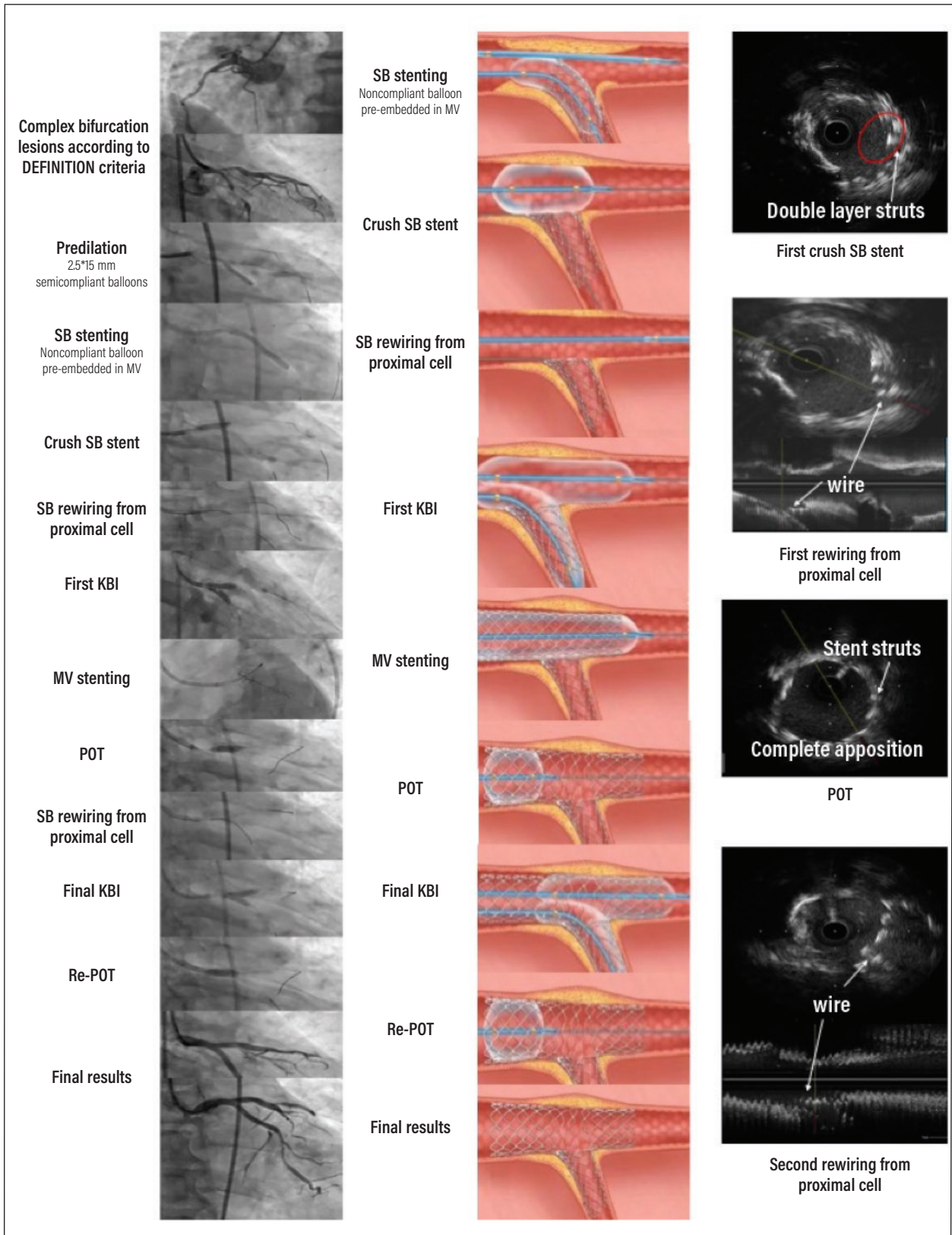


Figure 1. A step-by-step description of the DK crush technique.

6-F, 3.5-mm EBU guide catheter is engaged into the LM ostium via right radial access. Predilate the LCX and LAD using a 2.5- X 15-mm semicompliant balloon. Then, after intracoronary administration of nitroglycerin (100-200 µg), advance an IVUS catheter at least 10 mm distal to the LAD and LCX lesions. Acquire on-site IVUS images to assess the launch RVD, minimal lumen diameter, minimal lumen area, external elastic membrane diameter, plaque burden, lesion length, and plaque morphology and features; select the appropriate stent size; and identify the stent landing zone (Figure 1).

### Step 1: SB Stenting

Based on IVUS measurements, position a 3- X 29-mm DES in the LCX, with a protrusion of 2 to 3 mm into the LM. Simultaneously position a 3.5- X 12-mm non-compliant balloon in the LM-LAD. Deploy an LCX stent at > 12 atm, then remove the stent balloon and LCX wire after confirming there are no angiographic complications.



## TECHNICAL TIPS

- A stent/artery ratio of 1.1:1 by visualization is recommended if the procedure is guided by angiography.
- Before removing the LCX balloon, a noncompliant balloon is usually used to fully expand the LCX stent.

### Step 2: Balloon Crushing

Size the LAD balloon according to proximal LAD diameter (1:1 ratio) and inflate it to crush the LCX stent (to avoid jailing the LCX stent in the ostial LAD). Generally, the LM is much bigger than the proximal LAD. Accordingly, size a second large noncompliant balloon to the LM to achieve complete crushing of the LCX stent, which is confirmed by IVUS.



## TECHNICAL TIPS

- Beyond identifying the incomplete crushing, IVUS is very useful to show the position of rewiring. We always recommend rewiring from the proximal cell of the LCX stent.
- Orthogonal projections are simply to confirm the accuracy of the SB (eg, spiderview and cranial injections).

### Step 3: First KBI

After successfully rewiring the LCX from the proximal stent cell, inflate a 3.5- X 12-mm noncompliant balloon in the LM-LAD and a 3- X 12-mm noncompliant balloon in the LM-LCX to perform the first KBI.



## TECHNICAL TIPS

- In cases where the noncompliant balloon cannot be easily advanced into the SB, critically assess the accuracy of the rewiring position. In this scenario, stepwise inflation from a 1.5-mm balloon is not recommended.
- Two noncompliant balloons should have a short (usually 2 mm) overlapping in the LM.

### Step 4: MV Stenting

Based on the IVUS results, deploy a 3.5- X 33-mm DES to the LM-LAD to further crush the LCX stent, followed by postdilatation using a 3.5- X 12-mm noncompliant balloon and the proximal optimal technique (POT) using a 4.5- X 8-mm noncompliant balloon according to IVUS measurement.



## TECHNICAL TIPS

- The MV stent is also sized using the proximal LAD diameter.
- Operators should be aware of the expandable diameter of different stents. As an example, a 3-mm-diameter Synergy (Boston Scientific Corporation) stent cannot be expanded to 4.5 mm.

### Step 5: Final KBI

Once the LCX rewiring is confirmed by IVUS, inflate a 3.5- X 12-mm noncompliant balloon in the LM-LAD and another 3- X 12-mm noncompliant balloon in the LM-LCX at 12 atm to perform the final KBI.



## TECHNICAL TIPS

- Alternative inflation at > 16 atm starting from the LCX to the LAD is crucial to ensure there is no gap between the stent struts and carina and to maximally expand the stent in the polygon of confluence.

VISIT **CITODAY.COM**

to watch a video of the DK crush technique.

**Step 6: Final POT**

Complete the final POT and postdilation (not into either LAD or LCX) with a 4.5- X 8-mm noncompliant balloon. Perform final IVUS assessments to ensure the success of the DK crush procedure.

**SUMMARY**

The DK crush technique is associated with a reduced rate of clinical events for complex bifurcation lesions stratified by DEFINITION criteria compared to PS.<sup>4,11</sup> DK crush stenting consists of two-times kissing, crushing, and POT. ■

1. Al Suwaidi J, Yeh W, Cohen HA, et al. Immediate and one-year outcome in patients with coronary bifurcation lesions in the modern era (NHLBI dynamic registry). *Am J Cardiol.* 2001;87:1139-1144. doi: 10.1016/s0002-9149(01)01482-5
2. Colombo A, Jabbour RJ. Bifurcation lesions: no need to implant two stents when one is sufficient! *Eur Heart J.* 2016;37:1929-1931. doi: 10.1093/eurheartj/ehw185
3. Neumann FJ, Sousa-Uva M, Ahlsson A, et al. 2018 ESC/EACTS guidelines on myocardial revascularization. *Eur Heart J.* 2019;40:87-165. doi: 10.1093/eurheartj/ehy394
4. Zhang JJ, Ye F, Xu K, et al. Multicentre, randomized comparison of two-stent and provisional stenting techniques in patients with complex coronary bifurcation lesions: the DEFINITION II trial. *Eur Heart J.* 2020;41:2523-2536. doi: 10.1093/eurheartj/ehaa543
5. Chen SL, Zhang JJ, Han Y, et al. Double kissing crush versus provisional stenting for left main distal bifurcation lesions: DKCRUSH-V randomized trial. *J Am Coll Cardiol.* 2017;70:2605-2617. doi: 10.1016/j.jacc.2017.09.1066
6. Chen SL, Xu B, Han YL, et al. Comparison of double kissing crush versus Culotte stenting for unprotected distal left main bifurcation lesions: results from a multicenter, randomized, prospective DKCRUSH-III study. *J Am Coll Cardiol.* 2013;61:1482-1488. doi: 10.1016/j.jacc.2013.01.023

7. Chen SL, Santoso T, Zhang JJ, et al. Clinical outcome of double kissing crush versus provisional stenting of coronary artery bifurcation lesions: the 5-year follow-up results from a randomized and multicenter DKCRUSH-II study (randomized study on double kissing crush technique versus provisional stenting technique for coronary artery bifurcation lesions). *Circ Cardiovasc Interv.* 2017;10:e004497. doi: 10.1161/CIRCINTERVENTIONS.116.004497
8. Chen SL, Santoso T, Zhang JJ, et al. A randomized clinical study comparing double kissing crush with provisional stenting for treatment of coronary bifurcation lesions: results from the DKCRUSH-II (double kissing crush versus provisional stenting technique for treatment of coronary bifurcation lesions) trial. *J Am Coll Cardiol.* 2011;57:914-920. doi: 10.1016/j.jacc.2010.10.023
9. Zhang J, Gao X, Kan J, et al. Intravascular ultrasound versus angiography-guided drug-eluting stent implantation: the ULTIMATE trial. *J Am Coll Cardiol.* 2018;72:3126-3137. doi: 10.1016/j.jacc.2018.09.013
10. Medina A, Suarez de Lezo J, Pan M. [A new classification of coronary bifurcation lesions] [Article in Spanish]. *Rev Esp Cardiol.* 2006;59:183.
11. Chen SL, Sheiban I, Xu B, et al. Impact of the complexity of bifurcation lesions treated with drug-eluting stents: the DEFINITION study (definitions and impact of complex bifurcation lesions on clinical outcomes after percutaneous coronary intervention using drug-eluting stents). *JACC Cardiovasc Interv.* 2014;7:1266-1276. doi: 10.1016/j.jcin.2014.04.026

**Jun-Jie Zhang, MD**

Department of Cardiology  
Nanjing First Hospital  
Nanjing Medical University  
Nanjing, China

*Disclosures: None.*

**Shao-Liang Chen, MD**

Department of Cardiology  
Nanjing First Hospital  
Nanjing Medical University  
Nanjing, China

chmengx@126.com

*Disclosures: None.*